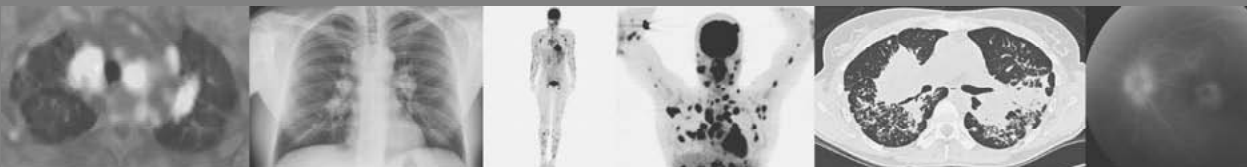

Chapter 5

Severity of pulmonary involvement and ^{18}F -FDG PET activity in sarcoidosis



RLM Mostard, JA Verschakelen, MJPG van Kroonenburgh,
PJ Nelemans, PAHM Wijnen, S Vöö, M Drent

Submitted

Abstract

Background

Assessing inflammatory activity is useful in the management of persistent symptomatic sarcoidosis patients. ^{18}F -FDG PET (PET) appeared to be a sensitive technique to assess inflammatory activity in sarcoidosis. The aim of this study was to evaluate whether the severity of the pulmonary involvement is associated with PET activity in persistent symptomatic sarcoidosis patients.

Methods

Over a 5-year period, relevant clinical data including laboratory and lung function test results were gathered from the medical records of 95 sarcoidosis patients with persistent disabling symptoms who underwent both a PET and a high-resolution computed tomography (HRCT). HRCT scans were classified using a semi-quantitative scoring system and PET findings as positive or negative, respectively.

Results

PET was positive in 77/95 patients, of whom 56 demonstrated pulmonary PET-positivity. HRCT scores were high (7.1 ± 3.6) in patients with positive pulmonary PET findings ($n=56$) compared to patients with negative pulmonary PET findings ($n=39$; 3.0 ± 2.9 ; $p<0.001$). The diffusion capacity for carbon monoxide (DLCO) (65 ± 20 % predicted) and the forced vital capacity (FVC) (85 ± 24 % predicted) were low in patients with pulmonary PET-positivity versus those with negative pulmonary PET findings (79 ± 16 % predicted; $p=0.001$ and 96 ± 22 % predicted; $p=0.044$, respectively). Interestingly, out of the 26 patients with fibrotic changes, 22 (85%) had positive pulmonary PET findings, of whom 18/22 (82%) showed extrathoracic PET-positive lesions and 16/22 (73%) showed signs of serological inflammation.

Conclusions

The severity of the pulmonary involvement, assessed by HRCT features and lung function parameters, appeared to be associated with increased PET activity in sarcoidosis. The majority of patients with fibrotic changes demonstrated inflammatory activity, next to pulmonary also at extrathoracic sites.

Introduction

Sarcoidosis is a multisystemic disease characterized by activity of cellular immunity with formation of noncaseating granuloma in various organ systems.¹ The majority of deaths from sarcoidosis results from respiratory failure and no universal definition exists for what constitutes 'active' pulmonary disease. It is therefore important to accurately assess pulmonary involvement. The reliable detection of changes in pulmonary disease severity in sarcoidosis by using chest radiography and lung function testing has proved problematic.² Forced vital capacity (FVC) and the diffusing capacity for carbon monoxide (DLCO) have been regarded as the most accurate pulmonary function measures of pulmonary involvement in sarcoidosis and deterioration is regarded as an indicator of disease activity in sarcoidosis.^{2,3} However, assessment of disease activity through lung function tests requires evidence of progression between two measurements and so does not reflect the current status. Moreover, lung function testing cannot distinguish between reversible granulomatous lesions and irreversible fibrotic changes, and correlates only modestly with the level of dyspnea reported by patients.^{3,4} Although chest radiography (CXR) is most often the first diagnostic imaging study for assessment of pulmonary involvement in sarcoidosis, the radiographic score (stages 0-IV) possesses limited value in predicting inflammatory activity.^{1,5-7}

The high-resolution CT (HRCT) uses short scanning times and thin collimation, making it possible to demonstrate lung parenchyma in detail and detect abnormal changes of the lung parenchyma at an early stage.⁸ The presence and extent of parenchymal abnormalities on HRCT has been found to correlate with respiratory functional impairment in sarcoidosis.^{6,9-13} However, HRCT is a morphological imaging technique that provides only indirect information on the underlying metabolic changes. Due to pre-existing major abnormalities, HRCT features are therefore frequently of limited value for the assessment of inflammatory activity in sarcoidosis patients with pulmonary fibrosis, since it is not possible to differentiate between fibrotic and residual granulomatous components in the parenchymal consolidations.

¹⁸F-FDG PET/CT (PET) is used to detect high glucose metabolism and has been shown to be useful for the assessment of inflammatory activity in sarcoidosis.¹⁴⁻¹⁸ Recently, elevated serological inflammatory markers were found to be associated with PET-positivity.¹⁹ To date, only limited information is available about the relationship between morphological- and functional pulmonary abnormalities, and metabolic changes as measured by PET findings in sarcoidosis patients.

The aim of the present study was to evaluate whether the severity of pulmonary involvement as assessed by HRCT features and lung function parameters is associated with PET activity in sarcoidosis.

Materials and methods

We reviewed the medical records of all sarcoidosis patients referred to the interstitial lung disease service (ild care team) of the department of Respiratory Medicine at the Maastricht University Medical Centre (Maastricht, The Netherlands), a tertiary referral center, between June 2005 and September 2010. All sarcoidosis patients who underwent both a PET and a HRCT (n=106) were included. The indication for performing the PET was the presence of unexplained disease related disabling symptoms that persisted for at least one year. Persistent disabling symptoms were defined as the presence of more than one symptom that had substantial influence on quality of life, and that could not be explained with the results of routine investigations, including the absence of lung functional or chest radiographic deterioration. These symptoms included fatigue (Fatigue Assessment Scale [FAS] ≥ 22),²⁰ symptoms compatible with small fiber neuropathy (SFN; SFN Screenings List [SFNSL] score ≥ 11),²¹ arthralgia and/or muscle pain, dyspnea (MRC dyspnea scale ≥ 3), exercise intolerance or coughing. Laboratory and lung-function testing were performed within a 2-week interval before or after the HRCT. PET scans were made within a 3-months interval before or after the HRCT, without changing the therapy during this period. In all cases, patients had a clinical presentation compatible with sarcoidosis. The diagnosis was based on consistent clinical features and bronchoalveolar lavage (BAL) fluid analysis results, according to the international guidelines.¹ The diagnosis was confirmed histological, demonstrating noncaseating epithelioid cell granulomas, in most cases (75%). Patients with known co-morbid conditions associated with PET positive findings were excluded. Therefore, five patients with common variable immunodeficiency (CVID), five patients with malignancy and one patient with both rheumatoid arthritis and amyloidosis were excluded. After exclusion for these criteria, 95 patients were selected. The study protocol was approved by the Medical Research Ethics Committee of our institution.

Laboratory tests

Serum angiotensin-converting enzyme (ACE) was measured by colorimetric method (cat. no. FU 116; Fujirebio Inc.), the reference interval was 9-25 U/l. Serum levels of soluble interleukin-2 receptor (sIL-2R) were analyzed in commercially available Diaclone ELISA kits (Sanquin, Amsterdam, The Netherlands) and considered elevated if >3154 pg/l. Serum levels of neopterin were evaluated by a competitive ELISA (IBL; Hamburg, Germany). Serum levels were considered elevated if >2.5 ng/l. Results for combined serological inflammatory marker testing (ACE, sIL-2R and neopterin) were considered positive if at least one of the serological inflammatory markers was elevated.

C-reactive protein (CRP) was measured using a turbidimetric method performed using the Beckman synchron CX-7 system (kit 465231; Mijdrecht, The Netherlands). The detection limit for CRP was 2 µg/ml, with a normal range of 2-9 µg/ml.

Chest radiography

According to the Scadding radiographic staging system, five stages of radiographic abnormality (0-IV) were recognized.¹

Lung function tests

FVC was measured with a pneumotachograph (Masterlab, Jaeger, Würzburg, Germany). DLCO was measured by the single-breath method (Masterlab, Jaeger, Würzburg, Germany). Values were expressed as a percentage of predicted values.²²

Imaging

Thin-section scans with 1-mm collimation were obtained at 10-mm intervals through the chest (Somaton Plus, Siemens, Erlangen, Germany). The scanning parameters included 137 kVP, 255 mA, and 1-s scanning time. Both mediastinal (width 400 HU, level 40 HU) and lung (width 1600 HU, level -800 HU) window images were obtained. Scans were reconstructed with a high-frequency reconstruction algorithm.

A whole body ¹⁸F-FDG PET/CT scan was performed using a Gemini[®] PET-CT (Philips Medical Systems) scanner with time-of-flight (TOF) capability, together with a 64-slice Brilliance CT scanner. Patients were fasting for at least six hours before the examination. In all patients blood glucose was measured to ensure that the blood glucose was below 10 mmol/ml. ¹⁸F-FDG (GE Health, Eindhoven, The Netherlands) was injected intravenously and followed by physiologic saline (10 ml). The injected total activity of FDG depended on the weight of the patient. Mean injected dose was: 200 MBq. After a resting period of 45 minutes (time needed for uptake of FDG) PET and CT images were acquired from the head to the feet. A low dose CT-scan was performed without intravenous contrast and was used for attenuation correction of the PET images. The PET images were acquired in 5-minute bed positions. The complete PET data set was reconstructed iteratively with a reconstruction increment of 5 mm to provide isotropic voxel.

Image analysis

An experienced thoracic radiologist (JV), blinded to the patient's clinical history and to the PET findings, classified the scans of both lungs using a semiquantitative HRCT scoring system that has been described by Oberstein et al.¹³ and that has been used in previous studies of our group.⁶ This scoring system is explained in detail in Table 5.1.

Table 5.1 Definition of abnormal high-resolution computed tomography (HRCT) findings in sarcoidosis, adapted from Oberstein et al.¹³, visual score.

	Lung volume affected ^a			
	No lesions: 0	<33%:1	<66%:2	>66%:3
Typical patterns of parenchymal involvement				
BVB				
PC				
ND				
LS				
	Pathological findings ^b			
	None: 0	Minor:1	Moderate: 2	Pronounced:3
PL				
LN				

BVB: thickening or irregularity of the bronchovascular bundle; PC: parenchymal consolidation (including ground-glass opacifications); ND: intraparenchymal nodules; LS: septal and nonseptal lines; PL: focal pleural thickening; LN: enlargement of the mediastinal lymph nodes

The total score is obtained by adding up the individual scores (BVB, ND, LS, PC, LN, and PL)

^a The lung volume affected is quantified by a visual score: 0=no lesions found; 1=up to 33%; 2=up to 66%; and 3=more than 66% of the volume affected

^b The PL and the enlargement of the LN (with a short axis of 1 cm or more considered enlarged) were quantified: 0=no pathological findings; 1=minor; 2=moderate; and 3=pronounced changes

Separately, the presence of signs of fibrosis (architectural distortion as shown by distortion of the airways and blood vessels, irregular distortion of the septal and intralobular lines, retraction of the hila and fissures, cystic formation and traction bronchiectasis)^{23,24} was evaluated.

All PET were interpreted by an experienced nuclear medicine physician (MvK), blinded to the patient's clinical history and to the HRCT findings. PET findings in the lungs, lymph nodes, or other soft tissues or bones were scored as either positive or negative. A positive PET-scan interpretation was performed visually, with a threshold standardized uptake value (SUVmax) ≥ 2.5 . ¹⁸F-FDG uptake was quantified by drawing a region of interest around the area of pathology of the co-registered transaxial slice. SUVmax was calculated as the maximal pixel activity within the region of interest. The degree of increased metabolic activity in the pulmonary parenchyma needed to be higher than the mediastinal background.

In a next step in a consensus meeting between radiologist and nuclear medicine physician, in the patients with pulmonary PET-positivity, the area of most intensive thoracic ¹⁸F-FDG uptake was identified and the HRCT pattern in this region was assessed. This predominant HRCT substrate of thoracic ¹⁸F-FDG uptake was classified as one of the items included in the HRCT score. Inter-reader reliability of the total HRCT score and of the simple PET classification system we used proved to be very good, as reported in previous studies with the same observers (weighted kappa 0.99 and 1.00, respectively).^{6,19} Accordingly, in the present study, observation by a single radiologist and a single nuclear physician was regarded to be sufficient.

Statistical procedure

Statistical analyses were performed using SPSS, version 15.0 for Windows. Differences were tested for statistical significance using the Student's t-test for independent samples in case of continuous variables or chi-square test in case of categorical variables. A p-value of <0.05 (two sided) was considered to indicate statistical significance.

Receiver operating characteristic (ROC) curves were constructed to evaluate the ability of the total HRCT score and the HRCT subscores to predict the presence of PET-positive results. Area under the curve (AUC) values with 95% confidence intervals (CI) were used to quantify and visualise the strength of the association.

Results

In Table 5.2, relevant demographic and clinical characteristics of the studied sarcoidosis patients (87 Caucasians, five of African origin and three of Asian origin) categorized by absence (n=39: 41%) or presence (n=56: 59%) of positive PET findings in the pulmonary parenchyma are summarized. The median SUVmax in the PET-positive patients was 7.0 (2.5-24.2).

Forty patients (71%) in the pulmonary PET-positive group demonstrated one or more extrathoracic lesions. In the pulmonary PET-negative group, 21 patients had extrathoracic positive PET findings. Extrathoracic positive PET findings in the sarcoidosis patients categorized by absence or presence of positive PET findings in the pulmonary parenchyma are shown in Table 5.3.

Relation between morphological and metabolic changes

Association between HRCT (sub)scores and pulmonary PET-positivity

The total HRCT score as well as the subscores of the 56 patients with pulmonary PET-positivity was high compared with the 39 patients with pulmonary PET-negativity (see Table 5.4).

ROC curve results for the association between the total HRCT score and pulmonary PET-positive results are presented in Figure 5.1. The AUC was 0.81 (95% CI: 0.73-0.90). The AUCs of the various HRCT patterns as included in the HRCT score are presented in Table 5.5. All patients with a total HRCT score >9 (n=17) had positive PET findings and all patients with a total HRCT score >10 (n=16) had pulmonary positive PET findings. None of the patients with a total HRCT score of 0 points (n=11) had pulmonary PET-positive findings, nevertheless five of them had extrathoracic positive PET findings and two of them showed increased serological inflammatory markers.

Table 5.2 Demographic and clinical characteristics of the sarcoidosis patients categorized by absence or presence of positive PET findings in the pulmonary parenchyma.

	Pulmonary parenchyma PET - patients (n=39)	Pulmonary parenchyma PET + patients (n=56)	p-value
Age (yrs)	44 (22-72)	48 (24-76)	NS
Sex (male)	22 (56%)	33 (59%)	NS
Time since diagnosis (yrs)	2 (1-20)	2 (1-21)	NS
Therapy total number (%)	9 (23%)	17 (30%)	NS
1/2/3/4	4/1/4/0	9/6/1/1	NS
ACE (9-25 U/l)	15 (1-35)	19 (3-60)	0.030
sIL-2R (240- 3154 pg/ml)	2028 (518-9662)	3451 (1191-15000)	0.004
Neopterin (<2.5 ng/ml)	1.7 (0.8-2.8)	3.0 (0.7-18.2)	0.004
CRP (2-9 µg/ml)	4 (1-80)	6 (1-70)	NS
CXR stage 0/I	22/7	8/9	0.016
CXR stage II/III/IV	2/5/3	11/5/23	NS
FVC total (% pred)	96±22	85±24	0.044
CXR 0-I	98±22	105±11	NS
CXR II-IV	91±24	80±20	NS
DLCO total (% pred)	79±16	65±20	0.001
CXR 0-I	81 ±16	76±19	NS
CXR II-IV	71±16	60±19	NS
RFI total	21/39 (54%)	45/56 (81%)	0.008
CXR 0-I	14/29 (48%)	11/17 (65%)	NS
CXR II-IV	7/10 (70%)	34/39 (87%)	NS

Data are presented as median with range in parentheses; mean±SD; absolute numbers or percentages if appropriate. PET: positron emission tomography; -: negative; +: positive; n:number; yrs: years; NS: not significant; therapy total: total number of patients treated at time of PET scanning; 1: prednisone monotherapy; 2: methotrexate monotherapy; 3: prednisone and methotrexate combination therapy; 4: methotrexate and infliximab combination therapy; ACE: serum angiotensin-converting enzyme; sIL-2R: soluble interleukin-2 Receptor; CRP: C-reactive protein; CXR: chest X-ray; FVC: forced vital capacity; % pred: percentage of predicted values; DLCO: diffusion capacity for carbon monoxide; RFI: respiratory functional impairment, defined as present if DLCO was <80%, FEV1 was <80%, or FVC was <80% of the predicted value. p<0.05 was considered to indicate significance.

Table 5.3 Extrathoracic and mediastinal positive PET findings in the sarcoidosis patients categorized by absence or presence of positive PET findings in the pulmonary parenchyma.

Extrathoracic and mediastinal positive PET findings	Pulmonary parenchyma PET - patients (n=39; CXR 0-I/II-IV: 29/10)	Pulmonary parenchyma PET + patients (n=56; CXR 0-I/II-IV: 17/39)
Mediastinal lymph nodes	15 (39%)	43 (77%)
Peripheral lymph nodes	18 (46%)	38 (68%)
Liver	0	9 (16%)
Spleen	2 (5%)	14 (25%)
Parotid glands	4 (10%)	13 (23%)
Skin	1 (3%)	1 (2%)
Bone	7 (18%)	16 (29%)
Central nervous system	0	1 (2%)

Data are presented as absolute numbers with percentages in parentheses; PET: positron emission tomography; n=number; CXR: chest X-ray

Table 5.4 HRCT features of the sarcoidosis patients categorized by absence or presence of positive PET findings in the pulmonary parenchyma.

	Pulmonary parenchyma PET - patients (n=39)	Pulmonary parenchyma PET + patients (n=56)	p-value
Total HRCT score	3.0 ±2.9	7.1±3.6	<0.001
BVB score	0.4±0.7	1.3±1.1	<0.001
ND score	0.6±0.7	1.3±0.9	<0.001
LS score	0.3±0.5	0.8±0.8	0.001
PC score	0.4±0.6	1.0±0.8	0.001
PL score	0.5±0.8	1.3±1.0	<0.001
LN score	0.8±1.1	1.5±0.9	0.002
Fibrosis on HRCT	4 (10%)	22 (39%)	0.002

Data are presented as mean±SD; absolute numbers or percentages if appropriate. PET: positron emission tomography; -: negative; +: positive; n: number; HRCT: high-resolution computed tomography; BVB: thickening or irregularity of the bronchovascular bundle; PC: parenchymal consolidation (including ground-glass opacifications); ND: intraparenchymal nodules; LS: septal and nonseptal lines; PL: focal pleural thickening; LN: enlargement of the mediastinal lymph nodes. p<0.05 was considered to indicate significance.

Table 5.5 Area under the curve (AUC) values for the association between positive pulmonary parenchymal results and the different HRCT patterns as included in the HRCT score.

	AUC	Confidence interval
BVB	0.75	0.65-0.85
ND	0.72	0.61-0.82
LS	0.68	0.58-0.79
PC	0.75	0.58-0.80
PL	0.68	0.65-0.85
LN	0.81	0.57-0.80

AUC: area under the curve; HRCT: high-resolution computed tomography; BVB: thickening or irregularity of the bronchovascular bundle; PC: parenchymal consolidation (including ground-glass opacifications); ND: intraparenchymal nodules; LS: septal and nonseptal lines; PL: focal pleural thickening; LN: enlargement of the mediastinal lymph nodes

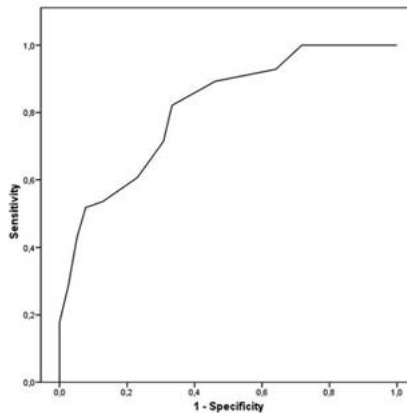


Figure 5.1 Reciever operating characteristic (ROC) curve of the association between the total HRCT score and positive PET results. AUC 0.81; CI 0.73-0.90

Predominant HRCT pattern on area of most intensive thoracic ^{18}F -FDG uptake

The predominant HRCT pattern on the area of most intensive thoracic ^{18}F -FDG uptake were parenchymal consolidations in 48%, lymph nodes in 25%, intraparenchymal nodules in 21%, septal and non-septal lines in 4% and pleural thickening in 2% of the patients, respectively.

Presence of fibrosis on HRCT

Signs of fibrosis on HRCT were present in 26 patients. The majority (22/26; 85%) of these patients showed positive pulmonary PET findings. Median SUVmax in these patients was 7.1 (3.1-16.2). Extrathoracic PET-positive findings were present in 18 (82%) and positive combined serological inflammatory marker testing in 16 (73%), respectively. An example of pulmonary PET-positivity in a sarcoidosis patient with fibrotic changes on HRCT is shown in Figure 5.2.

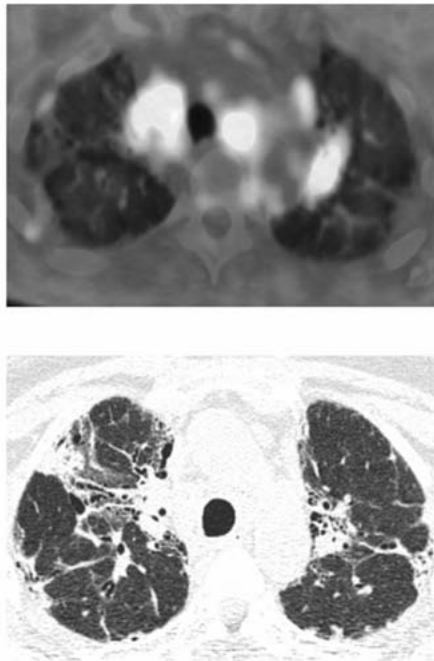


Figure 5.2 Example of pulmonary PET-positivity in a 45-year-old female sarcoidosis patient with fibrotic changes on HRCT.

The transversal PET/CT fusion image at thoracic level (upper image) shows areas of FDG accumulation bilateral in the hilar regions and in several mediastinal lymph nodes. The HRCT image (lower image) at the same level shows architectural parenchymal distortion with parenchymal opacities, thickening and irregularity of the bronchovascular bundle, irregular pleural thickening and in the left lung a limited area of honeycombing.

Relation between functional tests and metabolic changes

Association between lung function and pulmonary PET-positivity

In the PET-positive patient group, DLCO was lower in patients with pulmonary PET-positivity (65 ± 20 % predicted) versus the patients with exclusively extrapulmonary PET-positivity (79 ± 16 % predicted; $p=0.001$). The predictive value for PET-positivity of a model based on lung function parameters expressed by the AUC was for FVC and DLCO 0.62 (CI 0.49-0.74) and 0.73 (CI 0.60-0.83), respectively. All patients with $DLCO < 45\%$ ($n=8$) or $FVC < 50\%$ ($n=3$) showed positive pulmonary PET findings.

Discussion

In this study, we demonstrated that the severity of pulmonary involvement as assessed by HRCT features and lung function parameters is associated with pulmonary PET activity in sarcoidosis. Remarkably, inflammatory activity appeared to be present in the majority of patients with signs of fibrosis on HRCT.

HRCT features and PET findings

All HRCT features included in the used HRCT scoring system were associated with pulmonary PET positivity. Previous follow-up CT studies in patients with pulmonary sarcoidosis have shown that nodular opacities represent potentially reversible findings, and thus the presence of inflammatory activity in these nodules could be expected.^{24,25} However, the use of HRCT findings to identify the presence of residual active, reversible lesions in a background of fibrosis is much more difficult. The previously mentioned follow-up CT scan studies showed that cystic air spaces and architectural distortion are irreversible findings, with or without treatment.^{24,25} Based on the results of the present study, these latter findings do not exclude the presence of associated potentially reversible pulmonary parenchymal lesions, though. The used HRCT scoring system was criticized in the past because of the lack of an included fibrosis score.⁶ Therefore, in the present study the presence of signs of fibrosis on HRCT was scored separately. The majority of patients with signs of fibrosis on HRCT and CXR had positive pulmonary PET findings. Increased FDG uptake has also been observed in patients with idiopathic pulmonary fibrosis (IPF).²⁶⁻²⁹ All of the models proposed for the pathogenesis of pulmonary fibrosis involve a central role for fibroblasts, which are known to express glucose transporter-1.^{27,30} It is tempting to speculate that the elevated FDG uptake in patients with fibrotic changes, including honeycombing, might be a reflection of increased fibroblast metabolism and not due to inflammatory activity *sensu strictu*. In contrast to IPF patients, the majority of the pulmonary PET-positive sarcoidosis patients with fibrosis on HRCT in our population showed extrathoracic PET-positive findings (82%) and increased serological

inflammatory markers (73%). Furthermore, mean SUVmax (7.1 ± 3.6) in these patients was higher than reported by two studies with IPF patients^{26,27} (0.99 ± 0.29 and 2.9 ± 1.1 , respectively). These findings strongly suggest that PET-positive findings in sarcoidosis patients with CXR stage IV are indeed related to inflammatory activity.

Deciding which sarcoidosis patients with pulmonary fibrosis may benefit from pharmacological treatment remains a challenge to clinicians, as it is not always clear whether respiratory symptoms in these patients are a result of organ damage or due to ongoing inflammation or both. Careful consideration also needs to be given to the likely benefits of any therapy, set against the risk of adverse events, since adding the burden of medication like corticosteroids to these disabled patients might harm them even further. To date, there is no medication with the capability of reversing fibrosis, but there is hope that treatment can arrest fibrosis of reversible granulomas that persist among the fibrotic elements.³¹ This is in line with the results of the post-hoc analysis in the Sarcoidosis Investigators study, which suggested a greater benefit of infliximab therapy in patients with more severe disease, including radiographic stage IV.³² Techniques that are purported to differentiate fibrotic tissue from granulomatous tissue with inflammatory activity are therefore of importance. There is little evidence to support corticosteroid or immunosuppressive treatment of fibrotic lung disease unless the presence of inflammatory activity can be demonstrated.³¹

Several reports have demonstrated a significant reduction of FDG uptake after the initiation or modification of treatment in sarcoidosis patients.^{16,18,33-35} Keijsers et al.³³ demonstrated that changes in PET-imaging in a small cohort of sarcoidosis patients treated with infliximab considerably correlated with clinical signs of improvement. Another study showed that diffuse pulmonary parenchymal activity in sarcoidosis patients, as imaged by ¹⁸F-FDG PET, predicted a future deterioration of DLCO when medical treatment was withheld, while treatment with corticosteroids or immunosuppressive drugs significantly improved lung function.³⁶ Teirstein et al.¹⁸ described that the improvement of symptoms, conventional imaging findings, and physiological data paralleled the therapy-related decrease in SUVmax as seen on the PET scans in most patients, including three patients with radiographic stage IV. Although the exact importance of the presence of inflammatory activity for treatment decisions obviously needs to be established in future prospective, longitudinal studies, the above-mentioned findings support the clinical and therapeutic relevance of positive PET findings in sarcoidosis. Moreover, the detection of PET-positive extrathoracic lesions can be helpful to differentiate between sarcoidosis and other ild like IPF in patients presenting with pulmonary fibrosis.

HRCT appeared to be superior to CXR for presuming positive pulmonary PET findings because pulmonary PET-positivity was assessed or excluded with specific values of the total HRCT score (in case of respectively >10 and 0 points). A positive relation was found between pulmonary positive PET findings and higher CXR stages, however, CXR stage 0 did not exclude positive pulmonary PET findings (27% had positive pulmonary PET findings) and a minority of patients (12%) with CXR stage IV had negative

pulmonary PET findings. It should be noted that although all patients with a total HRCT score of 0 points (n=11) had negative pulmonary PET findings, five of them demonstrated extrathoracic positive PET findings. This warrants the use of other diagnostic tools like PET for assessment of inflammatory activity in patients with persistent disabling symptoms in the absence of lung functional deterioration or serological signs of inflammatory activity and with no or limited (total HRCT score<10) radiologic abnormalities.

Lung function and PET findings

The relationship between respiratory functional impairment and morphological abnormalities on HRCT is well established in sarcoidosis patients.^{6,12,23,37} The present study demonstrated a relationship between decreased lung function and pulmonary PET-positivity. This is in accordance with the above-mentioned study of Keijsers et al.³⁶ and with a study in a population of patients with mixed interstitial lung disease.²⁷ In the present study, PET-positivity was demonstrated in all patients with a DLCO<45% or FVC<50%. Further studies are required to prove whereas these values can be adopted as threshold for clinical use.

This study has several limitations. First, the study population was gathered in a referral centre for sarcoidosis, so the refractory character of the disease may have been more severe than in a general sarcoidosis population. Follow-up of the patients was generally performed by their own physicians and therefore no standardized follow-up data were available for analysis. Second, HRCT and PET were not performed in every referred patient, since only part of the patients was referred because of unexplained persistent disease related symptoms. This might cause a selection bias. The questions asked by the referring physicians and the reasons for referring the patients to our centre were very diverse and these investigations were not necessary in all patients to answer the questions appropriately. However, this does not mean that these patients had less severe sarcoidosis.

In conclusion, the severity of pulmonary involvement as assessed by HRCT features and lung function parameters was associated with increased PET activity in sarcoidosis. Interestingly, inflammatory activity was demonstrated by positive PET findings, next to pulmonary also extrathoracic (82%), as well as by serological signs of inflammatory activity (73%) in the majority (85%) of patients with radiological fibrotic changes.

References

1. Costabel U, Hunninghake GW. ATS/ERS/WASOG statement on sarcoidosis. Sarcoidosis Statement Committee. American Thoracic Society. European Respiratory Society. World Association for Sarcoidosis and Other Granulomatous Disorders. *Eur Respir J* 1999;14:735-7.
2. Keir G, Wells AU. Assessing pulmonary disease and response to therapy: which test? *Semin Respir Crit Care Med* 2011;31:409-18.
3. Consensus conference: activity of sarcoidosis. Third WASOG meeting, Los Angeles, USA, September 8-11, 1993. *Eur Respir J* 1994;7:624-7.
4. Baughman RP, Culver DA, Judson MA. A concise review of pulmonary sarcoidosis. *Am J Respir Crit Care Med* 2011;183:573-81.
5. DeRemee RA. The roentgenographic staging of sarcoidosis. Historic and contemporary perspectives. *Chest* 1983;83:128-33.
6. Drent M, De Vries J, Lenters M, Lamers RJ, Rothkranz-Kos S, Wouters EF, van Dieijen-Visser MP, Verschakelen JA. Sarcoidosis: assessment of disease severity using HRCT. *Eur Radiol* 2003;13:2462-71.
7. Baughman RP, Shipley R, Desai S, Drent M, Judson MA, Costabel U, du Bois RM, Kavuru M, Schlenker-Herceg R, Flavin S, Lo KH, Barnathan ES. Changes in chest roentgenogram of sarcoidosis patients during a clinical trial of infliximab therapy: comparison of different methods of evaluation. *Chest* 2009;136:526-35.
8. Verschakelen JA. The role of high-resolution computed tomography in the work-up of interstitial lung disease. *Curr Opin Pulm Med* 2010;16:503-10.
9. Remy-Jardin M, Giraud F, Remy J, Wattinne L, Wallaert B, Duhamel A. Pulmonary sarcoidosis: role of CT in the evaluation of disease activity and functional impairment and in prognosis assessment. *Radiology* 1994;191:675-80.
10. Bergin CJ, Bell DY, Coblentz CL, Chiles C, Gamsu G, MacIntyre NR, Coleman RE, Putman CE. Sarcoidosis: correlation of pulmonary parenchymal pattern at CT with results of pulmonary function tests. *Radiology* 1989;171:619-24.
11. Leung AN, Brauner MW, Caillat-Vigneron N, Valeyre D, Grenier P. Sarcoidosis activity: correlation of HRCT findings with those of 67Ga scanning, bronchoalveolar lavage, and serum angiotensin-converting enzyme assay. *J Comput Assist Tomogr* 1998;22:229-34.
12. Abehsera M, Valeyre D, Grenier P, Jaillet H, Battesti JP, Brauner MW. Sarcoidosis with pulmonary fibrosis: CT patterns and correlation with pulmonary function. *AJR Am J Roentgenol* 2000;174: 1751-7.
13. Oberstein A, von Zitzewitz H, Schweden F, Muller-Quernheim J. Non invasive evaluation of the inflammatory activity in sarcoidosis with high-resolution computed tomography. *Sarcoidosis Vasc Diffuse Lung Dis* 1997;14:65-72.
14. Keijsers RG, Grutters JC, Thomeer M, Du Bois RM, Van Buul MM, Lavalaye J, Van Den Bosch JM, Verzijlbergen FJ. Imaging the inflammatory activity of sarcoidosis: sensitivity and inter observer agreement of (67)Ga imaging and (18)F-FDG PET. *Q J Nucl Med Mol Imaging* 2011;55:66-71.
15. Nishiyama Y, Yamamoto Y, Fukunaga K, Takinami H, Iwado Y, Satoh K, Ohkawa M. Comparative evaluation of 18F-FDG PET and 67Ga scintigraphy in patients with sarcoidosis. *J Nucl Med* 2006;47: 1571-6.
16. Braun JJ, Kessler R, Constantinesco A, Imperiale A. 18F-FDG PET/CT in sarcoidosis management: review and report of 20 cases. *Eur J Nucl Med Mol Imaging* 2008;35:1537-43.
17. Keijsers RG, Verzijlbergen FJ, Oyen WJ, van den Bosch JM, Ruven HJ, van Velzen-Blad H, Grutters JC. 18F-FDG PET, genotype-corrected ACE and sIL-2R in newly diagnosed sarcoidosis. *Eur J Nucl Med Mol Imaging* 2009;36:1131-7.
18. Teirstein AS, Machac J, Almeida O, Lu P, Padilla ML, Iannuzzi MC. Results of 188 whole-body fluorodeoxyglucose positron emission tomography scans in 137 patients with sarcoidosis. *Chest* 2007;132:1949-53.
19. Mostard RLM, Voo S, van Kroonenburgh MJPG, Verschakelen JA, Wijnen PAHM, Nelemans PJ, Erckens RJ, Drent M. Inflammatory activity assessment by F18 FDG-PET/CT in persistent symptomatic sarcoidosis *Respir Med* 2011;105:1917-24.

20. de Kleijn WP, Elfferich MD, De Vries J, Jonker GJ, Lower EE, Baughman RP, King TE Jr, Drent M. Fatigue in sarcoidosis: American versus Dutch patients. *Sarcoidosis Vasc Diffuse Lung Dis* 2009;26: 92-7.
21. Hoitsma E, De Vries J, Drent M. The small fiber neuropathy screening list: Construction and cross-validation in sarcoidosis. *Respir Med* 2011;105:95-100.
22. Quanjer PH, Tammeling GJ, Cotes JE, Pedersen OF, Peslin R, Yernault JC. Lung volumes and forced ventilatory flows. Report Working Party Standardization of Lung Function Tests, European Community for Steel and Coal. Official Statement of the European Respiratory Society. *Eur Respir J Suppl* 1993;16:5-40.
23. Akira M, Kozuka T, Inoue Y, Sakatani M. Long-term follow-up CT scan evaluation in patients with pulmonary sarcoidosis. *Chest* 2005;127:185-91.
24. Brauner MW, Lenoir S, Grenier P, Cluzel P, Battesti JP, Valeyre D. Pulmonary sarcoidosis: CT assessment of lesion reversibility. *Radiology* 1992;182:349-54.
25. Murdoch J, Muller NL. Pulmonary sarcoidosis: changes on follow-up CT examination. *AJR Am J Roentgenol* 1992;159:473-7.
26. Umeda Y, Demura Y, Ishizaki T, Ameshima S, Miyamori I, Saito Y, Tsuchida T, Fujibayashi Y, Okazawa H. Dual-time-point 18F-FDG PET imaging for diagnosis of disease type and disease activity in patients with idiopathic interstitial pneumonia. *Eur J Nucl Med Mol Imaging* 2009;36:1121-30.
27. Groves AM, Win T, Screaton NJ, Berovic M, Endozo R, Booth H, Kayani I, Menezes LJ, Dickson JC, Ell PJ. Idiopathic pulmonary fibrosis and diffuse parenchymal lung disease: implications from initial experience with 18F-FDG PET/CT. *J Nucl Med* 2009;50:538-45.
28. Meissner HH, Soo Hoo GW, Khonsary SA, Mandelkern M, Brown CV, Santiago SM. Idiopathic pulmonary fibrosis: evaluation with positron emission tomography. *Respiration* 2006;73:197-202.
29. Nusair S, Rubinstein R, Freedman NM, Amir G, Bogot NR, Izhar U, Breuer R. Positron emission tomography in interstitial lung disease. *Respirology* 2007;12:843-7.
30. Ortiz PA, Haspel HC. Differential control of the functional cell surface expression and content of hexose transporter GLUT-1 by glucose and glucose metabolism in murine fibroblasts. *Biochem J* 1993;295 (Pt 1):67-72.
31. Teirstein AT, Morgenthau AS. "End-stage" pulmonary fibrosis in sarcoidosis. *Mt Sinai J Med* 2009;76:30-6.
32. Baughman RP, Drent M, Kavuru M, Judson MA, Costabel U, du Bois R, Albera C, Brutsche M, Davis G, Donohue JF, Muller-Quernheim J, Schlenker-Herceg R, Flavin S, Lo KH, Oemar B, Barnathan ES. Infliximab therapy in patients with chronic sarcoidosis and pulmonary involvement. *Am J Respir Crit Care Med* 2006;174:795-802.
33. Keijsers RG, Verzijlbergen JF, van Diepen DM, van den Bosch JM, Grutters JC. 18F-FDG PET in sarcoidosis: an observational study in 12 patients treated with infliximab. *Sarcoidosis Vasc Diffuse Lung Dis* 2008;25:143-9.
34. Mostard RL, Prompers L, Weijers RE, van Kroonenburgh MJ, Wijnen PA, Geusens PP, Drent M. F-18 FDG PET/CT for Detecting Bone and Bone Marrow Involvement in Sarcoidosis Patients. *Clin Nucl Med* 2012;37:21-5.
35. Milman N, Graudal N, Loft A, Mortensen J, Larsen J, Baslund B. Effect of the TNFalpha inhibitor adalimumab in patients with recalcitrant sarcoidosis: a prospective observational study using FDG-PET. *Clin Respir J* 2011 Nov 30 Epub ahead of print.
36. Keijsers RG, Verzijlbergen FJ, van den Bosch JM, Zanen P, van de Garde EM, Oyen WJ, Grutters JC. 18F-FDG PET as a predictor of pulmonary function in sarcoidosis *Sarcoidosis Vasc Diffuse Lung Dis* 2011;28:123-9.
37. Hansell DM, Milne DG, Wilsher ML, Wells AU. Pulmonary sarcoidosis: morphologic associations of airflow obstruction at thin-section CT. *Radiology* 1998;209:697-704.