

Interstitial Lung Damage Due to Cocaine Abuse: Pathogenesis, Pharmacogenomics and Therapy

M. Drent^{1,*}, P. Wijnen² and A. Bast³

¹Faculty of Health, Medicine and Life Science, University Maastricht & Dept. of Interstitial Lung Diseases & Respiratory Medicine, Hospital Gelderse Vallei, Ede; ²Dept. of Clinical Chemistry, Maastricht University Medical Centre (MUMC); ³Dept. of Toxicology, University Maastricht, Maastricht, The Netherlands

Abstract: Medicinal agents, beside occupational and environmental agents, remain one of the most common causes for interstitial lung diseases (ILD). A major problem with ILD is the recognition of the causative agent. In some cases more or less characteristic features of presentation are described. Often, the connection between drug-use and the development of related inflammatory damage or idiosyncratic toxicities is hard to recognize and objectify. Cocaine, a xenobiotic and the most commonly used illicit drug, causes serious medical and social problems. An increasing incidence of lung toxicity related to cocaine or crack-use is being reported worldwide. However, the mechanism of the resulting lung injury is not fully understood. This review summarizes possible molecular mechanisms explaining intra-individual variability in cocaine response and lung toxicity. The importance of including pharmacogenomics in the work-up of patients with suspected drug-induced lung toxicity is highlighted.

Keywords: Cocaine, crack, CYP450, drug-induced toxicity, interstitial lung diseases, polymorphisms, oxidative stress, redox cycling, nitroxide radicals, cocaine metabolites, biotransformation.

INTRODUCTION

Interstitial lung diseases (ILD) are a rapidly growing and increasingly complex component of clinical practice. They represent a group of heterogeneous disorders that diffusively involve the lung parenchyma. The term 'interstitial' was originally applied to these disorders because they are associated with thickening of the alveolar septum. The 'interstitium' is that part of the alveolar structures bounded by the alveolar epithelial and endothelial basement membranes. The normal alveolar interstitium is composed of connective tissue components (e.g. collagen, elastic fibers, mesenchymal cells), and inflammatory and immune effector cells (monocytes/macrophages and lymphocytes). Generally, ILD involve alveolar epithelial and endothelial cells as well. In addition, although these diseases primarily attack the alveolar structures (inflammation and fibrosis), many also involve airways, arteries, and veins [1, 2]. ILD can lead to diffuse remodelling and architectural damage to normal lung tissue and progressive loss of lung function. Well over 100 different types of ILD have been identified on the basis of clinical presentation, causes, radiographic findings, and histopathologic examination [3-5].

Drug-induced interstitial lung damage or disease (DI-ILD) is the most common form of drug-induced respiratory disease. The drugs involved not only include prescribed and over-the-counter drugs, but also illicit drugs, herbs, alcohol, and dietary ingredients, see also Table 1 [6-9]. An ever increasing number of drugs can produce or reproduce variegated patterns of naturally-occurring infiltrative lung disease [6, 8, 10]. Although, only in a limited number of cases drugs unequivocally have been identified as cause, it is important to acknowledge the potential role of medication in the development of drug-induced ILD [6, 11]. This is due to the severity of the potentially irreversible damage to the lungs and the improvement that is often easily achieved by stopping administration of drugs. The diagnosis of DI-ILD and other toxic effects of drug use primarily rests on the temporal association of exposure to drug(s), and the development of respiratory symptoms [6]. It is also challenging to identify those cases that are at risk of developing such a reaction and avoiding re-challenge with the trigger.

Cocaine causes medical and social problems. It is the most commonly used illicit drug among patients seen in emergency departments and is the most frequent cause of drug-related deaths reported by medical examiners [12]. Cocaine and marijuana are very popular illicit drugs, acting as stimulants of the central nervous system. Cocaine is a naturally occurring alkaloid that can be extracted from leaves of the *Erythroxylon coca* plant. It is available in four forms: hydrochloride salt, 'freebase', 'crack', and 'bazuco'. Crack cocaine is considered to be the most potent and addictive form of the drug and smoking is the preferred method of intake for many drug users. Adulterants are found in street samples of cocaine and result in additional toxicity. Among the most common adulterants are local anesthetics, sugars, stimulants (e.g. caffeine, ephedrine), toxins (e.g. quinine, strychnine), and inert compounds (e.g. inositol, talc, cornstarch, silica), as well as other substances (e.g. flour, aspirin, plaster) [12]. Crack is a white, crystalline freebase form of cocaine that, unlike the powder form of the drug, may be smoked.

COCAINE-INDUCED INTERSTITIAL LUNG DAMAGE

Besides heart rhythm disturbances, acute and chronic parenchymal lung injuries are not uncommon complications resulting from inhalation of these drugs in habitual drug users [12]. Pulmonary complications of cocaine are influenced by the method of administration, the dose, and the presence of associated substances. The mechanism of the resulting lung injury is not fully understood, but a direct toxic effect of the inhaled agent, occurring in a dose-dependent pattern, is most highly suspected [12].

A wide variety of pulmonary complications associated with the inhalation of (crack) cocaine have been described, including interstitial pneumonitis and fibrosis, pulmonary hypertension, diffuse alveolar hemorrhage (DAH), diffuse alveolar damage (DAD), asthma exacerbation, barotrauma, and thermal airway injury.

The findings of acute noncardiogenic edema, DAH, cryptogenic organizing pneumonia (COP), and pathologic evidence of acute lung injury in patients who died of acute crack cocaine overdose support the hypothesis that cocaine causes damage to the alveolar-capillary membrane. Additionally, Susskind *et al.* [13] showed increased lung permeability following long-term use of crack cocaine in seven subjects with the use of labeled technetium-99m-diethylenetriamine pentaacetic acid.

*Address correspondence to this author at the interstitial lung diseases, University Maastricht, Faculty of Health, Medicine and Life Science, UNS 40 room 4.550, PO Box 3100 6202 NC Maastricht, The Netherlands; Tel: +31 43 3882087; Fax: +31 842234007; E-mail: m.drent@maastrichtuniversity.nl

Table 1. Summary of the Categories of Substances Known to Cause Respiratory Problems with Some Examples of the Possible Causative Agents

Drugs (illicit)	Biomolecules	Blood/Stem-cells	Herbs/Dietary supplements	Miscellaneous
Amiodarone	Interferons	Retinoic acid	Ephedra	Talc
Cocaine	Immunoglobulins	Blood products	Comfrey	Silicone
Methotrexate	Anti-thymocyte globuline	Stem-cell transplantation	Germander	Mineral oil
Methadone		Blood transfusion	Aristolochic acid	
Nitrofurantoin				
Oral anticoagulants				

Cocaine also appears to have important immunomodulatory capacities. However, the mechanisms underlying cocaine-mediated immune regulation have not yet been fully characterized. One pathway whereby cocaine may influence immune responses is through modification of cytokine production by lymphocytes. Mao *et al.* [14] reported that cocaine down-regulated the production of interferon-gamma (IFN- γ) and IL-8 by human peripheral blood lymphocytes (PBL) through reducing the transcriptional rate of these cytokine genes. These latter findings suggest that the immune modulatory effects of cocaine may be mediated, in part, by decreased production of IFN- γ and IL-8 by PBL. It is well known that IFN- γ plays a central role in several aspects of cell-mediated immune responses, as well as in the pathogenesis of ILD.

Dicpinigaitis *et al.* [15] described a patient with a clinical presentation strongly suggestive of sarcoidosis with diffuse interstitial pulmonary infiltrates and bilateral hilar adenopathy. Evaluation of lung biopsy showed perivascular and peribronchial histiocytic interstitial infiltrates and the presence of polarizable foreign material in the lung as well as the thoracic lymph node biopsies. Presumably, chronic inhalation of crack cocaine by the reported patient induced a diffuse pulmonary reaction. This response may be a direct effect of cocaine or, alternatively, the lungs may be reacting to one of the many associated substances that may be inhaled along with crack cocaine.

One report of crack cocaine-associated interstitial pneumonitis with eventual respiratory failure demonstrated a histiocytic interstitial infiltrate with polarizable foreign material that was identified as crystalline silica. The similar microscopic appearance of the crystals in this case and the associated fibrotic nodule in the lymph node suggest that silica or a silica-like substance may have been the inciting agent.

Smoking of cocaine exposes the lung directly to the volatilized drug as well as to the other combustion products of the smoked mixture, thereby increasing the risk of adverse pulmonary effects. These complications include acute respiratory symptoms, pulmonary edema, asthma, pulmonary hemorrhage, 'crack lung', talcosis, and ILD [12]. Moreover, chronic inhalative cocaine abuse can cause foreign body associated granulomatosis, mimicking sarcoidosis of the lung and other organs. Different types of interstitial lung damage due to cocaine inhalation – including acute DAH, diffuse alveolar infiltrates, and eosinophilic infiltrates – have been described [16, 17]. Many inhaled chemicals are not hazardous as such but are bio-transformed into reactive intermediates [16].

MOLECULAR MECHANISM OF COCAINE-INDUCED LUNG DAMAGE

The Department of Pulmonary Diseases at the University Hospital of Dijon in France provides a very informative web site which mentions drugs that are suspected to cause lung damage (<http://www.pneumotox.com>). Considering the list of drugs that may damage the respiratory system it is striking that those compounds which have a high frequency of causing adverse interstitial lung effects are compounds which are known to generate reactive

oxygen species. Examples are the cytostatic drug bleomycin, the antibiotic nitrofurantoin or the antiarrhythmic agent amiodarone. Interestingly these compounds are oxygen radical generators. Bleomycin and nitrofurantoin produce $O_2^{\cdot-}$ via redox cycling (Fig. 1) [18, 19]. Amiodarone has been shown to produce hydroxyl radicals directly in a water solution [20]. Also the lung toxic herbicide paraquat (Fig. 2) generates $O_2^{\cdot-}$ via redox cycling [18]. This effective herbicide is prohibited because of its pulmonary toxicity. This led to the suggestion that reactive oxygen species are key players in the etiology of drug-induced lung damage [21]. This is underscored by the observation that stimulators of $O_2^{\cdot-}$ generating enzymes such as angiotensin II or endothelin are initiators of pulmonary fibrosis [21]. The question arises whether the lung toxicity of cocaine is also mediated via the formation of reactive oxygen species. This was already extensively hypothesized in 2005, but until now it has not really been experimentally established [22].

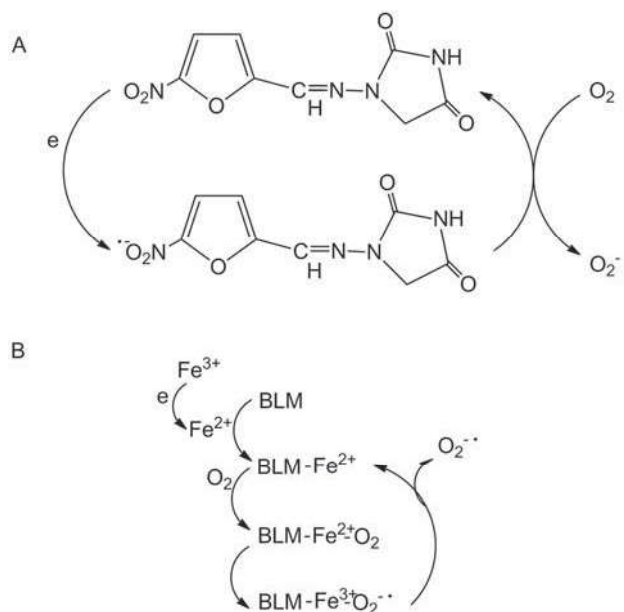


Fig. (1). Redox cycling of nitrofurantoin (Fig. 1A) and bleomycin (Fig. 1B). The nitro moiety of the antibiotic nitrofurantoin can be reduced which subsequently transfers the electron to O_2 , thus forming $O_2^{\cdot-}$. The free radical generation by the cytostatic bleomycin is iron dependent. A bleomycin-iron complex is reduced, i.e. takes up an electron which is then shuttled to O_2 thus forming $O_2^{\cdot-}$.

Cocaine is hydrolysed rapidly to the inactive benzoyl ecgonine, which is the main metabolite in blood and urine. Other significant metabolites are ecgonine methyl ester and ecgonine. Anhydroecgonine methyl ester, also known as methylecgonidine is a pyrrolytic substance formed by smoking cocaine. Coca ethylene is also found as a metabolite in persons who consume alcohol [23]. A minor route of metabolism is the formation of N-demethylated cocaine,

norcocaine (Fig. 3). This metabolite is formed by cytochrome P450 (CYP) 3A [24, 25] and is thought to be involved in the hepatotoxicity of cocaine [26].

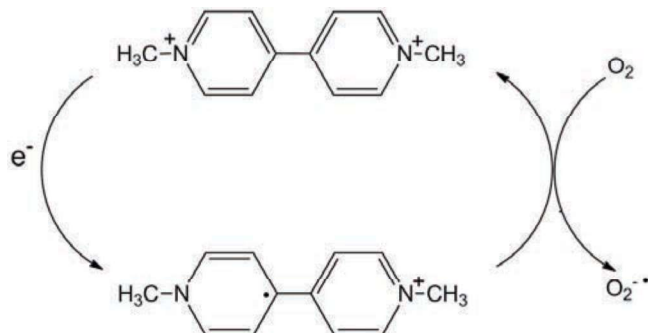


Fig. (2). The redox cycling of the herbicide paraquat, which leads to the production of superoxide anion radicals.

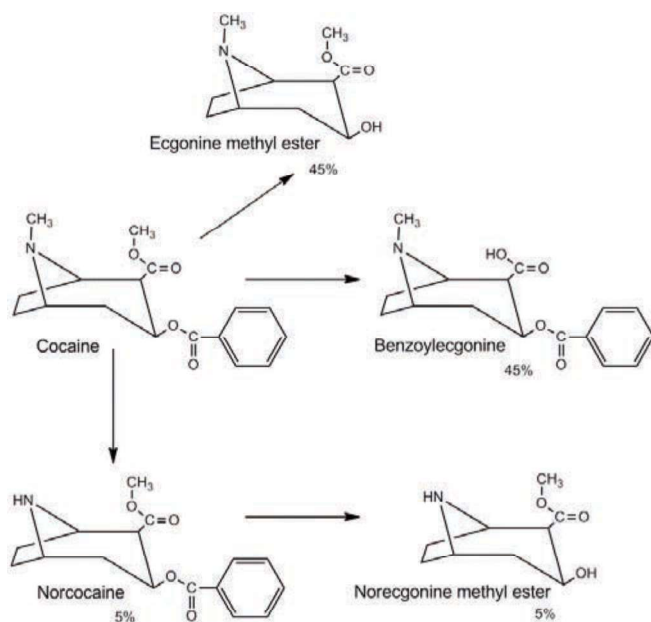


Fig. (3). Biotransformation of cocaine.

Interestingly, the mechanism of the hepatotoxicity of cocaine is thought to involve reactive oxygen species in particular $O_2^{\bullet-}$. Norcocaine is oxidized to N-hydroxynorcocaine which is further oxidized to norcocaine nitroxide [26]. The superoxide anion radical $O_2^{\bullet-}$ is generated during the reduction of norcocaine nitroxide radical to N-hydroxynorcocaine (Fig. 4). It has been suggested that this redox cycling process between N-hydroxynorcocaine and norcocaine nitroxide may lead to loss of cellular NADPH and to the simultaneous production of H_2O_2 [27]. In this process reduced glutathione (GSH) is consumed which may explain the hepatotoxicity (Fig. 4).

Not only in the liver but also in the central nervous system the role of oxidative stress induced by cocaine has been emphasised and has been related to the action of cocaine [28]. Adverse skin manifestations as observed in heavy cocaine abusers have also been related to enhanced oxidative stress in skin [29]. Cardiovascular dysfunction as a result of cocaine has also been related to oxidative stress [30]. It is conceivable that the lung toxicity may involve a similar process of redox cycling, production of $O_2^{\bullet-}$ leading to H_2O_2 and subsequent glutathione depletion. This likely mode of toxic action has to our knowledge still not been investigated.

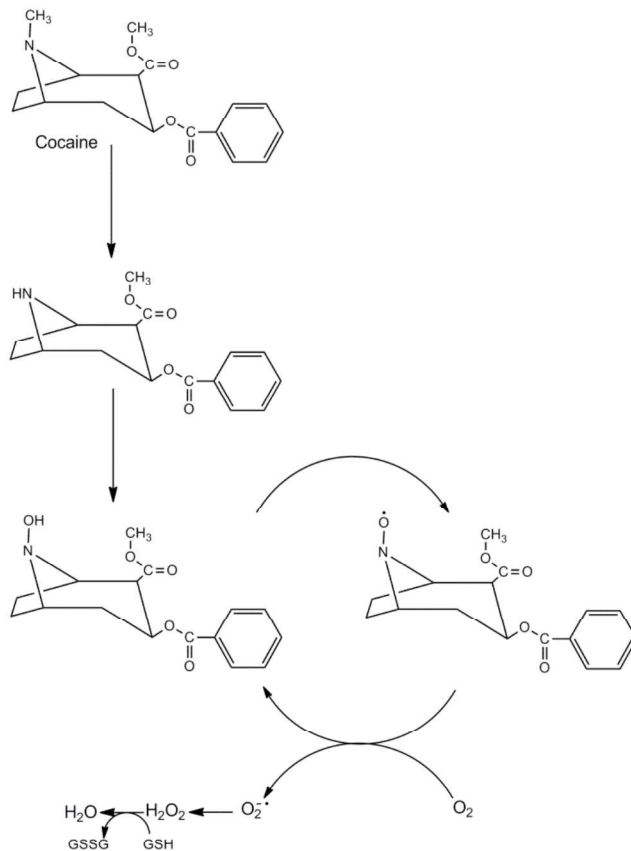


Fig. (4). Formation of norcocaine and subsequent redox cycling between the N-hydroxymetabolite of cocaine and the nitroxide radical of cocaine.

HOW DO REACTIVE OXYGEN SPECIES LEAD TO LUNG DAMAGE?

Two decades ago reactive oxygen species were primarily viewed as damaging species. Damage to DNA, protein or lipids can occur as a result of reaction with reactive oxygen species. A simple way to explain lung damage due to, for example, redox cycling. Emphasis currently is more on the physiological regulating role of reactive oxygen species. The $O_2^{\bullet-}$ is known to react with the vasodilating NO^* thus preventing its blood pressure lowering effect [31]. The vasoconstrictor effect that results from this interaction between $O_2^{\bullet-}$ and NO^* , might be responsible for the observed cocaine-induced pulmonary hypertension [12]. Pulmonary infarction secondary to severe local vascular spasm and in situ thrombosis may also result from crack cocaine smoking [32].

Recently, it was found that $O_2^{\bullet-}$ enters the lung fibroblast via chloride channels which then may lead to the generation of transforming growth factor beta (TGF- β) and to the formation of collagen [33]. Redox cycling may thus be critically involved in the etiology of lung fibrosis.

PHARMACOGENOMICS

The following could also be a possible explanation for lung damage by cocaine. Several different xenobiotic-metabolizing CYP and phase II enzymes have been found to be present in the human lung, contributing to in situ activation and inactivation of toxicants [34]. Although metabolism of foreign substances can be beneficial in eliminating potential toxins from the body by rendering the compounds more water soluble, in some instances the metabolic process can transform relatively harmless chemicals into toxic substances through metabolic bio-activation. Therefore, local metabolization

within lung tissue by these CYP enzymes, or the lack of, might explain adverse reactions and subsequent tissue damage [7, 35-38]. Furthermore, inter-individual differences in the expression of the involved CYP enzymes are assumed to contribute to the risk of developing ILD and other diseases initiated by agents that require metabolic activation or detoxification.

In a study by Wijnen *et al.* [7] it was shown that DI-ILD may be attributable to reduced metabolic capacity of CYP enzymes. The presence of CYP variant genotypes appeared to be a substantial susceptibility risk factor in the development of drug-induced pulmonary adverse events [7]. CYP2C9 and CYP2C19 belong to the largest CYP family and together with other members like CYP2D6 metabolize, to varying amounts, more than half of all frequently prescribed drugs [39]. Also, CYP2C9 and CYP2C19 are both inhibited by cocaine and CYP2C9 has a significant role in the detoxification of many xenobiotics such as cocaine, marijuana and its metabolites [24, 40]. Furthermore, it is known that besides the negative influence of cocaine on CYP2C enzymes, the added substances in laced cocaine can act as anticoagulants [12, 24]. Moreover, DAH caused by oral anticoagulants was associated with CYP and/or vitamin K epoxide reductase complex 1 (*VKORC1*) variant allele presence [41]. DAH with hemoptysis (reported in up to 26% of crack users) secondary to freebase cocaine smoking can be life threatening, with massive bleeding that may require surgery [42]. Smoking of laced (e.g. with rodenticide) cocaine or marijuana can have similar effects [43, 44]. The association of DAH with hypersensitivity pneumonitis has been considered in the pathophysiology of this acute syndrome, which usually responds to corticosteroids. In a case study by Wijnen *et al.* [45], the presented patients displayed a variant allele for the *VKORC1* enzyme, which has a profound influence on the vitamin K cycle and on vitamin K dependent clotting factors. When triggered by (illicit) drugs, an over-anticoagulation and subsequent DAH may occur. Moreover, the influence on the vitamin K cycle was strengthened by the presence of CYP2C allelic variants (making them intermediate metabolizers for marijuana and cocaine or its substitute methadone) in combination with CYP2C inhibition by cocaine use [24, 41]. This also stresses the benefit such patients might gain from prophylactic vitamin K supplementation to prevent adverse effects like bleeding complications, including DAH and DAD, in the future [41, 46, 47].

TREATMENT OPTIONS

Rational treatment of drug-toxicities in cases where the mechanism of toxicity is known is common clinical practice. However, often the connection with drug use and the development of related inflammatory damage or idiosyncratic toxicities is hard to recognize and objectify, especially in those cases using multiple drugs.

There is no special treatment for cocaine-induced ILD as the mechanisms are still not fully understood. The primary role for the clinician is the recognition that cocaine and crack have been associated with pulmonary injury. Most DI-ILDs, including cocaine-induced ILD, are reversible if the usage of the causative drug(s) is stopped in time. If symptoms develop, therapy is primarily supportive. When the suspected toxin i.e. cocaine is discontinued sufficiently early, a regression of the pulmonary damage and beneficial effect can be observed.

Additional treatment options include corticosteroids, antioxidants, vitamin K, and immunomodulators, such as cyclophosphamide, depending on the severity of the lung damage. For example, inhibitors of CYP3A can prevent the hepatotoxicity of cocaine [25]. It would be very interesting to see whether inhibitors of the metabolism of cocaine could also prevent the cocaine-induced lung damage [48]. Moreover, the use of antioxidants like N-acetylcysteine or quercetin or the iron chelator deferoxamine might be worthwhile to investigate [49, 50].

If the damage is already more serious other therapy options have to be considered. For example, hepatotoxicity in rodents can be attenuated by antioxidant treatment and cocaine-induced brain damage in mice can be inhibited by an antioxidant like vitamin E [28, 51]. Similar studies with antioxidants to prevent or improve cocaine-induced lung toxicity have not been done, not even in lab animals. Moreover, studies into prophylactic vitamin K administration have also not yet been conducted and this could be an important investigation, especially useful and eventually beneficial for individuals with *VKORC1* polymorphisms.

In general, inflammatory lung damage is treated with corticosteroids. Interestingly though, lung damage in which an oxidative stress component is involved appears to be less sensitive to corticoid treatment due to oxidative damage of histone deacetylase (HDAC) which is important in the action of corticosteroids [52].

CONCLUSIONS

An increasing incidence of lung toxicity related to cocaine or crack is being reported worldwide. There is limited knowledge of the mechanisms of cocaine-induced lung injury including ILD and restricted diagnostic tests are available. The clinician should consider this option in evaluating a patient with unexplained ILD. The diagnosis rests on the clinical picture, history taking and identifying the possible toxic agent. Re-challenge with cocaine is not indicated. The pulmonary long-term effects of cocaine use are diffuse alveolar damage, diffuse alveolar hemorrhage, eosinophilic pneumonia and cryptogenic organizing pneumonia.

It is imperative that clinicians consider cocaine use in their history taking and differential diagnosis when patients presenting with new pulmonary complaints. Discontinuing cocaine use is the best treatment option. Additional treatment options include corticosteroids, antioxidants, vitamin K and immunomodulators, such as cyclophosphamide, depending on the severity of the lung damage. Including pharmacogenomics in the work-up of patients with suspected drug-induced (cocaine) lung toxicity is becoming more and more important.

CONFLICT OF INTEREST

The author(s) confirm that this article content has no conflicts of interest.

ACKNOWLEDGEMENT

Declared none.

REFERENCES

- [1] Crystal RG, Gadek JE, Ferrans VJ, Fulmer JD, Line BR, Hunninghake GW. Interstitial lung disease: current concepts of pathogenesis, staging and therapy. *Am. J. Med.*, 1981; 70:542-568.
- [2] Travis WD, Hunninghake G, King TE, Jr., Lynch DA, Colby TV, Galvin JR, Brown KK, Chung MP, Cordier JF, du Bois RM, Flaherty KR, Franks TJ, Hansell DM, Hartman TE, Kazerooni EA, Kim DS, Kitaichi M, Koyama T, Martinez FJ, Nagai S, Midhun DE, Muller NL, Nicholson AG, Raghu G, Selman M, Wells A. Idiopathic nonspecific interstitial pneumonia: report of an American Thoracic Society project. *Am. J. Respir. Crit. Care Med.*, 2008; 177:1338-1347.
- [3] Meyer KC. Bronchoalveolar lavage as a diagnostic tool. *Semin. Respir. Crit. Care Med.*, 2007; 28:546-560.
- [4] Drent M, Mansour K, Linszen C. Bronchoalveolar lavage in sarcoidosis. *Semin. Respir. Crit. Care Med.*, 2007; 28:486-495.
- [5] Demedts M, Behr J, Buhl R, Costabel U, Dekhuijzen R, Jansen HM, MacNee W, Thomeer M, Wallaert B, Laurent F, Nicholson AG, Verbeken EK, Verschakelen J, Flower CD, Capron F, Petruzzelli S, De Vuyst P, van den Bosch JM, Rodriguez-Becerra E, Corvasce G, Lankhorst I, Sardina M, Montanari M. High-dose acetylcysteine in idiopathic pulmonary fibrosis. *N. Engl. J. Med.*, 2005; 353:2229-2242.
- [6] Camus P, Fanton A, Bonniaud P, Camus C, Foucher P. Interstitial lung disease induced by drugs and radiation. *Respiration*, 2004; 71:301-326.
- [7] Wijnen PA, Drent M, Nelemans PJ, Kuijpers PM, Koek GH, Neef C, Haenen

- GR, Bekers O. Role of cytochrome P450 polymorphisms in the development of pulmonary drug toxicity: a case-control study in the Netherlands. *Drug Saf.*, 2008; 31:1125-1134.
- [8] Foucher P, Biour M, Blayac JP, Godard P, Sgro C, Kuhn M, Vergnon JM, Vervloet D, Pfitzenmeyer P, Ollagnier M, Mayaud C, Camus P. Drugs that may injure the respiratory system. *Eur. Respir. J.*, 1997; 10:265-279.
- [9] Bressler R. Grapefruit juice and drug interactions. Exploring mechanisms of this interaction and potential toxicity for certain drugs. *Geriatrics*, 2006; 61:12-18.
- [10] Camus P, Kudoh S, Ebina M. Interstitial lung disease associated with drug therapy. *Br. J. Cancer*, 2004; 91 Suppl 2:S18-23.
- [11] Drent M, Singh S, Gorgels AP, Hansell DM, Bekers O, Nicholson AG, van Suylen RJ, du Bois RM. Drug-induced pneumonitis and heart failure simultaneously associated with venlafaxine. *Am. J. Respir. Crit. Care Med.*, 2003; 167:958-961.
- [12] Restrepo CS, Carrillo JA, Martinez S, Ojeda P, Rivera AL, Hatta A. Pulmonary complications from cocaine and cocaine-based substances: imaging manifestations. *Radiographics*, 2007; 27:941-956.
- [13] Susskind H, Weber DA, Volkow ND, Hitzemann R. Increased lung permeability following long-term use of free-base cocaine (crack). *Chest*, 1991; 100:903-909.
- [14] Mao JT, Huang M, Wang J, Sharma S, Tashkin DP, Dubinett SM. Cocaine down-regulates IL-2-induced peripheral blood lymphocyte IL-8 and IFN-gamma production. *Cell. Immunol.*, 1996; 172:217-223.
- [15] Dicipinigitis PV, Jones JG, Frymus MM, Folkert VW. "Crack" cocaine-induced syndrome mimicking sarcoidosis. *Am. J. Med. Sci.*, 1999; 317:416-418.
- [16] Tashkin DP. Airway effects of marijuana, cocaine, and other inhaled illicit agents. *Curr. Opin. Pulm. Med.*, 2001; 7:43-61.
- [17] Gotway MB, Marder SR, Hanks DK, Leung JW, Dawn SK, Gean AD, Reddy GP, Araoz PA, Webb WR. Thoracic complications of illicit drug use: an organ system approach. *Radiographics*, 2002; 22 Spec No:S119-135.
- [18] Kappus H. Oxidative stress in chemical toxicity. *Arch Toxicol*, 1987; 60:144-149.
- [19] Wang Y, Gray JP, Mishin V, Heck DE, Laskin DL, Laskin JD. Role of cytochrome P450 reductase in nitrofurantoin-induced redox cycling and cytotoxicity. *Free Radic. Biol. Med.*, 2008; 44:1169-1179.
- [20] Taylor MD, Antonini JM, Roberts JR, Leonard SS, Shi X, Gannett PM, Hubbs AF, Reasor MJ. Intratracheal amiodarone administration to F344 rats directly damages lung airway and parenchymal cells. *Toxicol. Appl. Pharmacol.*, 2003; 188:92-103.
- [21] Bast A, Weseler AR, Haenen GR, den Hartog GJ. Oxidative stress and antioxidants in interstitial lung disease. *Curr. Opin. Pulm. Med.*, 2010; 16:516-520.
- [22] Kovacic P, Cooksy AL. Unifying mechanism for toxicity and addiction by abused drugs: electron transfer and reactive oxygen species. *Med. Hypotheses*, 2005; 64:357-366.
- [23] Drummer OH. In Clarke's Analytical Forensic Toxicology. Jickells, S.; Negrusz, A., Eds.; The Pharmaceutical Press: London/Grayslake, 2008; pp. 13-42.
- [24] Pasanen M, Pellinen P, Stenback F, Juvonen RO, Raunio H, Pelkonen O. The role of CYP enzymes in cocaine-induced liver damage. *Arch Toxicol*, 1995; 69:287-290.
- [25] Pellinen P, Honkakoski P, Stenback F, Niemitz M, Alhava E, Pelkonen O, Lang MA, Pasanen M. Cocaine N-demethylation and the metabolism-related hepatotoxicity can be prevented by cytochrome P450 3A inhibitors. *Eur J Pharmacol*, 1994; 270:35-43.
- [26] Rauckman EJ, Rosen GM, Cavagnaro J. Norcocaine nitroxide. A potential hepatotoxic metabolite of cocaine. *Mol Pharmacol*, 1982; 21:458-463.
- [27] Kloss MW, Rosen GM, Rauckman EJ. Cocaine-mediated hepatotoxicity. A critical review. *Biochem. Pharmacol.*, 1984; 33:169-173.
- [28] Macedo DS, Vasconcelos SM, Andrade-Neto M, Belchior LD, Honorio Junior JE, Goncalves DO, Fonteles MM, Silva MI, Aguiar LM, Viana GS, de Sousa FC. Cocaine-induced status epilepticus and death generate oxidative stress in prefrontal cortex and striatum of mice. *Neurochem. Int.*, 2010; 56:183-187.
- [29] Portugal-Cohen M, Numa R, Yaka R, Kohen R. Cocaine induces oxidative damage to skin via xanthine oxidase and nitric oxide synthase. *J. Dermatol. Sci.*, 2010; 58:105-112.
- [30] Moritz F, Monteil C, Isabelle M, Bauer F, Renet S, Mulder P, Richard V, Thuillez C. Role of reactive oxygen species in cocaine-induced cardiac dysfunction. *Cardiovasc. Res.*, 2003; 59:834-843.
- [31] Weseler AR, Bast A. Oxidative stress and vascular function: implications for pharmacologic treatments. *Curr Hypertens Rep*, 2010; 12:154-161.
- [32] Delaney K, Hoffman RS. Pulmonary infarction associated with crack cocaine use in a previously healthy 23-year-old woman. *Am. J. Med.*, 1991; 91:92-94.
- [33] Qi S, den Hartog GJ, Bast A. Superoxide radicals increase transforming growth factor-beta1 and collagen release from human lung fibroblasts via cellular influx through chloride channels. *Toxicol. Appl. Pharmacol.*, 2009; 237:111-118.
- [34] Ben-Zaken Cohen S, Pare PD, Man SF, Sin DD. The growing burden of chronic obstructive pulmonary disease and lung cancer in women: examining sex differences in cigarette smoke metabolism. *Am. J. Respir. Crit. Care Med.*, 2007; 176:113-120.
- [35] Ding X, Kaminsky LS. Human extrahepatic cytochromes P450: function in xenobiotic metabolism and tissue-selective chemical toxicity in the respiratory and gastrointestinal tracts. *Annual review of pharmacology and toxicology*, 2003; 43:149-173.
- [36] Nishimura M, Yaguti H, Yoshitsugu H, Naito S, Satoh T. Tissue distribution of mRNA expression of human cytochrome P450 isoforms assessed by high-sensitivity real-time reverse transcription PCR. *Yakugaku Zasshi*, 2003; 123:369-375.
- [37] Sarikaya D, Bilgen C, Kamataki T, Topcu Z. Comparative cytochrome P450 -1A1, -2A6, -2B6, -2C, -2D6, -2E1, -3A5 and -4B1 expressions in human larynx tissue analysed at mRNA level. *Biopharmaceutics & drug disposition*, 2006; 27:353-359.
- [38] Carlson GP. Critical appraisal of the expression of cytochrome P450 enzymes in human lung and evaluation of the possibility that such expression provides evidence of potential styrene tumorigenicity in humans. *Toxicology*, 2008; 254:1-10.
- [39] Nebert DW, Russell DW. Clinical importance of the cytochromes P450. *Lancet*, 2002; 360:1155-1162.
- [40] Bland TM, Haining RL, Tracy TS, Callery PS. CYP2C-catalyzed delta9-tetrahydrocannabinol metabolism: kinetics, pharmacogenetics and interaction with phenytoin. *Biochemical pharmacology*, 2005; 70:1096-1103.
- [41] Wijnen PA, Linssen CF, Haenen GR, Bekers O, Drent M. Variant VKORC1 and CYP2C9 Alleles in Patients with Diffuse Alveolar Hemorrhage Caused by Oral Anticoagulants. *Molecular diagnosis & therapy*, 2010; 14:23-30.
- [42] Tashkin DP, Khalsa ME, Gorelick D, Chang P, Simmons MS, Coulson AH, Gong H, Jr. Pulmonary status of habitual cocaine smokers. *Am. Rev. Respir. Dis.*, 1992; 145:92-100.
- [43] Waien SA, Hayes D, Jr., Leonardo JM. Severe coagulopathy as a consequence of smoking crack cocaine laced with rodenticide. *N. Engl. J. Med.*, 2001; 345:700-701.
- [44] Spahr JE, Maul JS, Rodgers GM. Superwarfarin poisoning: a report of two cases and review of the literature. *Am J Hematol*, 2007; 82:656-660.
- [45] Wijnen PA, Bekers O, Drent M. Development of cocaine-induced interstitial lung damage in two CYP2C and VKORC1 variant allele carriers. *Molecular diagnosis & therapy*, 2011; 15:177-180.
- [46] Sconce E, Avery P, Wynne H, Kamali F. Vitamin K supplementation can improve stability of anticoagulation for patients with unexplained variability in response to warfarin. *Blood*, 2007; 109:2419-2423.
- [47] Sconce EA, Avery PJ, Wynne HA, Kamali F. Vitamin K epoxide reductase complex subunit 1 (VKORC1) polymorphism influences the anticoagulation response subsequent to vitamin K intake: a pilot study. *J Thromb Haemost*, 2008; 6:1226-1228.
- [48] Shuster L, Casey E, Welankiwar SS. Metabolism of cocaine and norcocaine to N-hydroxynorcocaine. *Biochem. Pharmacol.*, 1983; 32:3045-3051.
- [49] Zaragoza A, Diez-Fernandez C, Alvarez AM, Andres D, Cascales M. Mitochondrial involvement in cocaine-treated rat hepatocytes: effect of N-acetylcysteine and deferoxamine. *Br. J. Pharmacol.*, 2001; 132:1063-1070.
- [50] Boots AW, Drent M, de Boer VC, Bast A, Haenen GR. Quercetin reduces markers of oxidative stress and inflammation in sarcoidosis. *Clin. Nutr.*, 2011; 30:506-512.
- [51] Vitcheva V, Simeonova R, Krasteva I, Yotova M, Nikolov S, Mitcheva M. Hepatoprotective effects of saponarin, isolated from *Gypsophila trichotoma* Wend. on cocaine-induced oxidative stress in rats. *Redox Rep*, 2011; 16:56-61.
- [52] Barnes PJ, Ito K, Adcock IM. Corticosteroid resistance in chronic obstructive pulmonary disease: inactivation of histone deacetylase. *Lancet*, 2004; 363:731-733.